

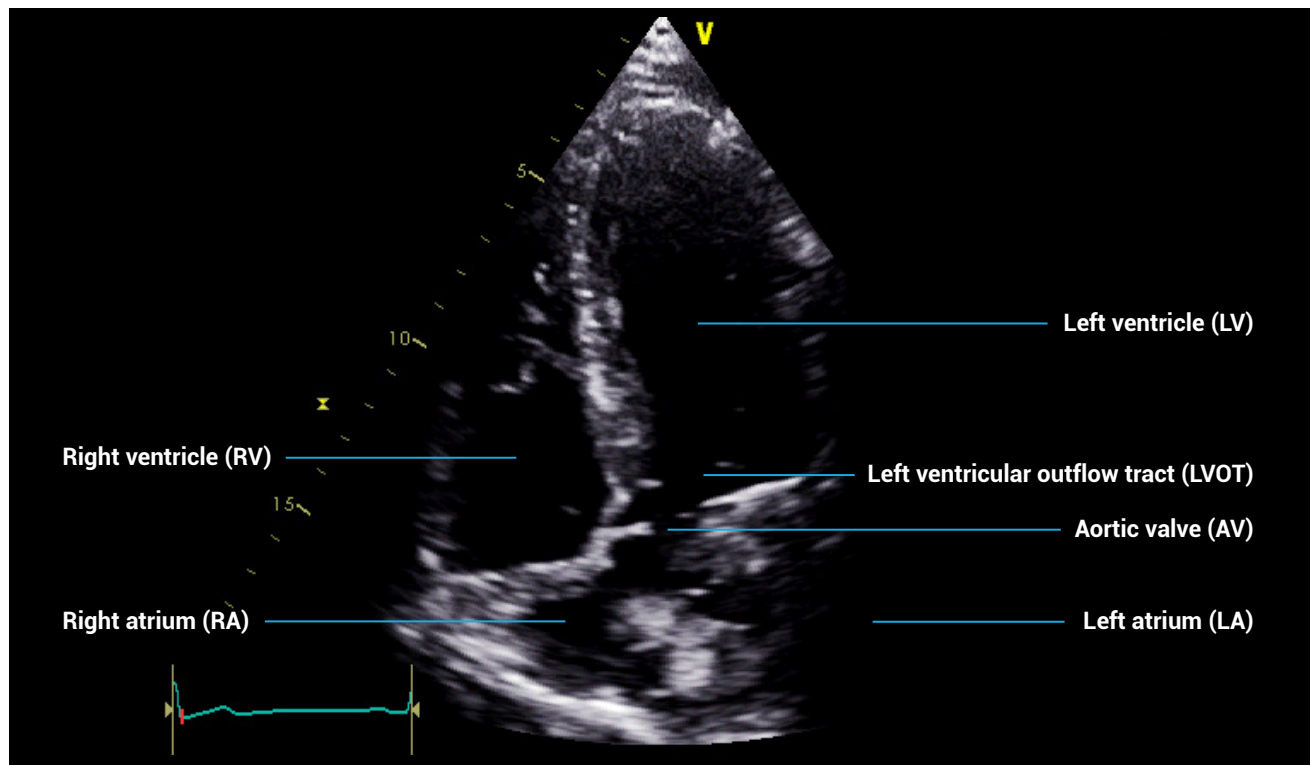
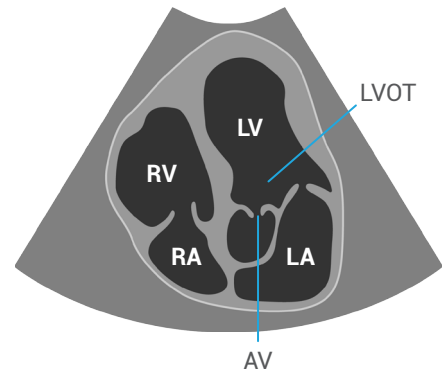
APICAL VIEWS

Mastering the apical five-chamber view

Patient position: lying on left side, left arm raised, raise the back of the bed or use pillows under the left shoulder

Probe position: over the apex beat, or V5 of ECG

Probe orientation: notch towards patient's left shoulder, tilt upwards from the four-chamber view



References and further reading:

1. European Society of Cardiology. 2017. *The EACVI Textbook of Echocardiography (2nd Edition)*. Lancellotti P, Zamorano JL, Habib G, and Badano L (Eds). Oxford, UK: Oxford University Press.
2. Anderson, B. 2006. *Echocardiography: The Normal Examination and Echocardiographic Measurements (2nd Edition)*. Hoboken, NJ: Wiley-Blackwell.
3. Wharton G, Steeds R, Allen J, et al. 2015. A minimum dataset for a standard adult transthoracic echocardiogram: a guideline protocol from the British Society of Echocardiography. <http://www.echopract.com/content/2/1/G9.full.pdf>